

EXTERNAL AND INTERNAL ROTATION

External Rotation (Lateral Rotation)

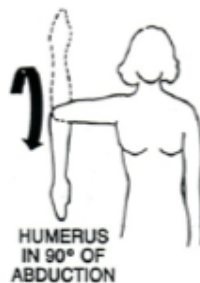
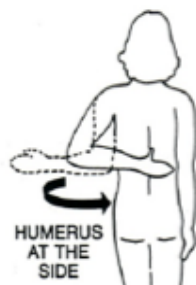
Muscles responsible:

Infraspinatus (rotator cuff)
Teres minor (rotator cuff)
Posterior Deltoid

Internal Rotation (Medial Rotation)

Muscles responsible:

Subscapularis (rotator cuff)
Anterior Deltoid
Pectoralis Major
Latissimus dorsi
Teres major



Note: There are more muscles that can cause internal rotation than external rotation. The pectoralis and latissimus muscles are more powerful than the external rotators and can override them, increasing the shearing forces on the humeral head.

